

# Surface Replacement Arthroplasty of the Proximal Interphalangeal Joint Using a Volar Approach: Case Series

Holbrook H. Stoecklein, BA, Rohit Garg, MBBS, Scott W. Wolfe, MD

**Purpose** To evaluate the outcomes (range of motion, function, and pain relief) of the volar approach to proximal interphalangeal (PIP) joint surface replacement arthroplasty (SRA) in active, high-demand patients.

**Methods** A single surgeon performed PIP SRA in 6 joints using a volar approach. Patients with posttraumatic arthritis or osteoarthritis of the PIP joint were included. Range of motion, postoperative key pinch and grip strength, and Disabilities of the Arm, Shoulder, and Hand questionnaire data were collected. Complications, component integration, and use of cement were noted. Average follow-up was 35 months (range, 12–66 mo).

**Results** Total arc of motion averaged 33° before surgery and improved significantly in all patients, for an average postoperative arc of motion of 60°. Grip strength averaged 30 kg in the affected hand and 35 kg in the contralateral hand after surgery. Postoperative key pinch strength averaged 6 and 7 kg in ipsilateral and contralateral hands, respectively. The average Disabilities of the Arm, Shoulder, and Hand score after surgery was 14. No coronal plane deformity or postural deformity was observed. Good component integration and stability were observed in all 5 cemented joints. The only noncemented joint demonstrated progressive subsidence of both components.

**Conclusions** The volar approach to PIP SRA can result in excellent range of motion, function, and pain relief with minimal complications in active patients with osteoarthritis or posttraumatic arthritis. The volar approach offers the advantages of maintaining the integrity of the extensor mechanism and allowing early postoperative motion. This case series demonstrates compelling data for a prospective, randomized study comparing dorsal and volar approaches to PIP SRA in patients with osteoarthritis and posttraumatic arthritis. (*J Hand Surg* 2011;36A:1015–1021. Copyright © 2011 by the American Society for Surgery of the Hand. All rights reserved.)

**Type of study/level of evidence** Therapeutic IV.

**Key words** Proximal interphalangeal joint, surface replacement arthroplasty, volar approach.

IMPLANT ARTHROPLASTY OF the proximal interphalangeal (PIP) joint has been practiced for more than half a century for treatment of patients with stiff, painful, and degenerated joints. It is primarily indicated in low-demand patients who wish to maintain motion at

the PIP joint. The earliest implants were the metallic or combination metal and plastic hinges designed by Brannon, Klein, and Flatt.<sup>1,2</sup> These were associated with wear at the hinge and high rates of prosthetic loosening and were eventually replaced by Swanson's silicone

From the Department of Orthopaedic Surgery, Hospital for Special Surgery; and the Weill Medical College of Cornell University, New York, NY.

Received for publication August 19, 2010; accepted in revised form March 7, 2011.

S.W.W. is a member of the Speaker's Bureau for Small Bone Innovations, Inc.

**Corresponding author:** Holbrook H. Stoecklein, 651 S. Belvedere Blvd., Memphis, TN 38104; e-mail: hstoecklein@gmail.com.

0363-5023/11/36A06-0009\$36.00/0  
doi:10.1016/j.jhssa.2011.03.003

**TABLE 1. Demographic Data**

Patient	Finger	Gender	Age (y)	Diagnosis	Follow up (mo)
1	Middle	F	54	Osteoarthritis	30
2	Ring	M	53	Posttraumatic arthritis	36
3	Ring	M	71	Osteoarthritis	66
4	Middle	M	31	Posttraumatic arthritis	30
5	Index, middle	F	89	Osteoarthritis, osteoarthritis	12

elastomer implant.<sup>3</sup> Further advances were marked by the advent of a 2-piece bicondylar design<sup>4</sup> for surface replacement arthroplasty (SRA). Surface replacement arthroplasty of the PIP joint has been traditionally performed using a cobalt-chromium proximal component and an ultra-high molecular weight polyethylene distal component<sup>3,5,6</sup> and, more recently, using pyrolytic carbon components.<sup>7-9</sup> Satisfactory pain relief and various degrees of restoration of joint motion have been reported for both Swanson's silicone implant<sup>7,10-14</sup> and SRA component designs.<sup>3,5-9</sup>

Several techniques for PIP implant arthroplasty have been described, including dorsal,<sup>3,6-9,12,14</sup> lateral,<sup>3,13</sup> and volar<sup>3,6, 10,11</sup> approaches. The possibility of bowstringing due to disruption of the flexor tendon sheath and violation of volar plate integrity have been cited as drawbacks to the volar approach.<sup>3</sup> However, proponents of the volar approach cite preservation of central slip integrity, avoidance of extensor mechanism adhesions, and the ability to begin immediate motion after surgery as distinct advantages. The lateral approach has the disadvantage of more extensive soft tissue disruption, including the collateral ligament complex, the volar plate, and the dorsal capsule. Dorsal approach advocates use both tendon splitting and tendon reflecting approaches, with no clear advantages of one over the other.

Similar outcomes have been reported for both dorsal and volar approaches to flexible silicone implant arthroplasty.<sup>7,10-14</sup> Herren and Simmen reported no difference in postoperative pain, stability, or range of motion (ROM) between these 2 approaches in a retrospective comparison.<sup>15</sup> However, in reports published for SRA of the PIP joint, the dorsal approach has been used exclusively<sup>5,8,9</sup> or in the vast majority of patients.<sup>3,6,7</sup> Only 16 cases have been reported in which the volar approach to SRA of the PIP joint was used,<sup>3,6</sup> and, to our knowledge, only 1 study<sup>6</sup> has reported the results separately for the 6 patients in whom the volar approach was used for SRA. Despite the advances in implant design and surgical approach, there is currently no

consensus as to what surgical approach yields optimal patient outcomes. This series describes the experience of the senior author (S.W.W.) with the volar approach to SRA of the PIP joint in a cohort of high-demand patients, all of whom are recreational golfers, with osteoarthritis or posttraumatic arthritis of the PIP joint.

## PATIENTS AND METHODS

### Demographics

This series reports the outcomes of 6 PIP surface replacement arthroplasties in 5 recreational golfers, performed by the senior author from 2002 to 2009 using the volar approach. The SR PIP implants (Small Bone Innovations, Inc., Morrisville, PA) were used in 1 index, 2 ring, and 3 middle finger PIP joints, all in the dominant hand, in 3 men and 2 women with osteoarthritis or posttraumatic degenerative arthritis (Table 1). One patient had concurrent distal interphalangeal joint arthrodesis in addition to the PIP SRA in her middle finger. Another patient had simultaneous PIP joint SRA for her left index and middle fingers. This same patient had previously undergone distal interphalangeal joint arthrodesis of her left middle finger. Two patients who had PIP SRA during the time period reported were not included. One had a diagnosis of inflammatory arthritis, and the other died of unrelated causes 6 months after her surgery. The average age at the time of surgery was 60 years (range, 28–88 y) and the average follow-up period was 35 months (range, 12–66 mo). Indications included pain, deformity, loss of motion in the affected digit, severe radiographic degenerative changes with complete loss of joint space, and failure of nonsurgical treatment for a minimum of 6 months. Contraindications included inflammatory arthropathy, previous infection, collateral ligament instability, central slip deficiency, severe angular deformity/bone loss, or previous surgery. The PIP implant arthroplasty was not offered for small finger involvement, due to border digit stability concerns and the small intermedullary canals.

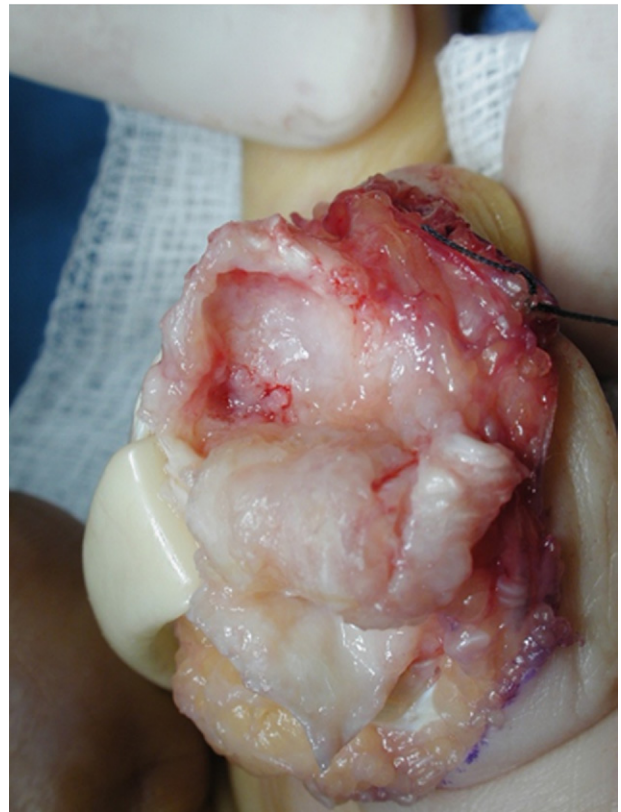
### Study design

The primary outcome parameter was the postoperative arc of motion, which was compared to preoperative arc of motion. Secondary outcome parameters included postoperative key pinch strength, grip strength, coronal plane deformity, postural deformity, and Disabilities of the Arm, Shoulder, and Hand (DASH) score. Complications, component integration, and use of cement were also noted. Medical records were reviewed retrospectively to obtain preoperative, intraoperative, and postoperative data. Follow-up DASH questionnaires were completed at the time of the final follow-up visit, except in the case of a single patient who completed the DASH questionnaire over the phone after the final follow-up visit. (Reported length of follow-up in this patient, as with all other patients, refers to the time of the final office visit.) All clinical measurements were made by a trained professional other than the senior author. A related-samples Wilcoxon signed ranks test was used to compare preoperative and postoperative arcs of motion ( $\alpha=0.05$ ). The study was reviewed and approved by the institution's internal review board.

### Surgical technique

The volar approach has been described previously,<sup>16</sup> but our approach differs slightly and is outlined in this article. A Bruner incision was made over the affected joint. The ulnar side of the flexor tendon sheath was incised between the A2 and A4 pulleys and reflected radially. The flexor digitorum superficialis and profundus tendons were retracted, and the ulnar and radial margins of the volar plate were separated from the accessory collateral ligaments. The volar plate was detached at its distal insertion on the middle phalanx and reflected proximally. The collateral ligaments were incised at their middle phalangeal insertions, allowing them to be reattached, at the conclusion of the case, to the repaired volar plate with a single suture. Care was taken throughout to protect the neurovascular bundles. The joint was then hyperextended to expose the articular surfaces (Fig. 1).

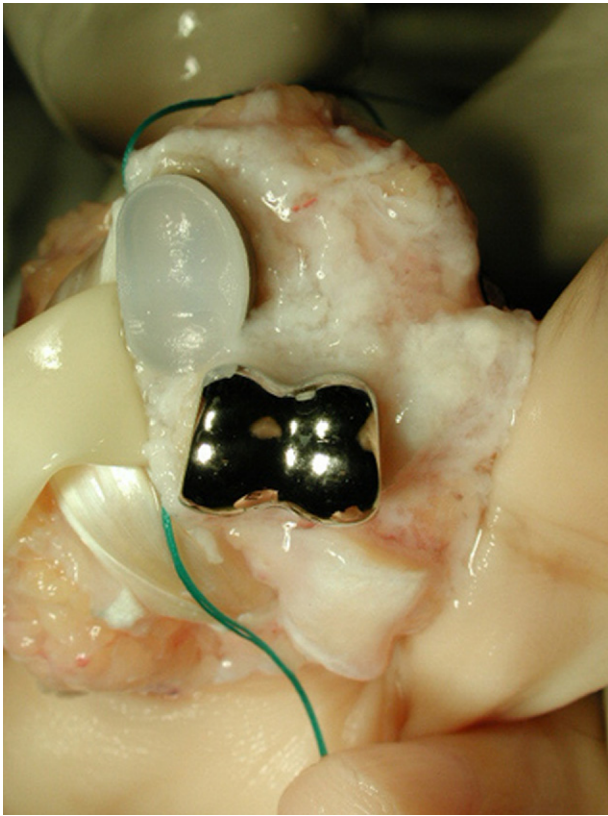
The subchondral bone of the middle phalanx and the head of the proximal phalanx, at the level of origin of the collateral ligaments, were removed. Using a Kirschner wire, we made 2 drill holes in the base of the middle phalanx for subsequent reattachment of the volar plate. The digit was reduced, and the cut surfaces were apposed to ensure neutral alignment of the digit in both the sagittal and coronal planes before the medullary canals of the proximal and middle phalanges were reamed. The intramedullary canals of the proximal



**FIGURE 1:** Articular surfaces were exposed after detachment of the volar plate and collateral ligaments.

and middle phalanges were broached to the same size, as the components are not interchangeable in size.

Trial components were then placed, the joint was reduced, and the flexor tendons were realigned. Joint tightness and fluidity of movement were assessed. Complete flexion of the joint without soft tissue resistance was crucial at this stage, and additional bony resection was carried out, if necessary, to ensure smooth joint motion. Care was taken with revision cuts to maintain the insertion of the central tendon on the base of the middle phalanx. Any angular or rotational malalignment was corrected before final implant insertion. Cement was prepared and injected into the medullary canals, and the final components were inserted into the canals using an impacting guide (Fig. 2). In a single case early in the series, in which cement was not used, a press-fit was obtained. The volar plate was reattached through drill holes in the base of the middle phalanx to prevent postoperative hyperextension, and the accessory collateral ligaments were reattached to the volar plate. A final motion check was performed to ensure full ROM, proper rotational alignment, and integrity of the volar plate reconstruction.



**FIGURE 2:** Final components were placed, with sutures pre-placed for reattachment of the volar plate.

The incision was closed, and a light dressing with a posterior plaster splint was applied. The dressing was removed and therapy begun within 3 days after surgery in all patients. A dorsal hand-based splint in full PIP extension was fabricated, and the patients were encouraged to remove the splint for active, active-assisted, and passive ROM exercises several times daily. Particular attention was paid to maintaining full PIP joint extension throughout the therapy program, using additional static progressive or gentle dynamic splinting if needed. Daytime splinting was discontinued at 4 weeks; night extension splinting was maintained for 2 to 4 additional weeks. Golf and recreational activities were allowed at 3 months, provided the digit was buddy-taped to an adjacent digit. A specific strengthening program was not used.

## RESULTS

Preoperative ROM averaged 22° (range, 5° to 35°) of flexion contracture to 54° (range, 45° to 65°) of flexion, for an average total arc of motion of 33° (range, 25° to 40°). After surgery, flexion contractures were eliminated in 3 of the 6 digits and were 15°, 30°, and 30° in the other 3 PIP joints, whereas flexion averaged 77°

(range, 65° to 85°) in all digits. Total arc of motion improved significantly ( $P = .03$ ) in all 6 digits, from 33° to an average of 60° (range, 40° to 85°) (Table 2).

Grip strength averaged 30 kg (range, 11–50 kg) in the affected hand and 35 kg (range, 16–55 kg) in the contralateral hand after surgery. Postoperative key pinch strength averaged 6 kg (range, 3–9 kg) in the ipsilateral and 7 kg (range, 4–10 kg) in the contralateral hand. Average DASH score after surgery was 14 and ranged from 1 to 33. It is notable that the highest score was seen in the elderly patient with diffuse degenerative disease throughout all digits, which might have confounded the results of her DASH score. Only 2 patients reported occasional pain at a level of 3 on a scale of 1 to 5, and 3 patients reported a level of 2 or less.

All patients continue to play golf regularly, without notable discomfort. No coronal plane deformity or postural deformity has been observed in any patient after surgery. No bowstringing of the flexor tendons was evident on clinical examination in any patient in this series. Good component integration and stability were observed in all 5 cemented joints. The noncemented joint demonstrated progressive subsidence of the proximal and distal components; however, at 66 months after surgery, the subsidence appears to have stabilized, the patient has no discomfort, and he plays golf regularly.

## DISCUSSION

Pain, limited motion, and joint destruction in the PIP joint can be managed with conservative measures, arthrodesis, or implant arthroplasty. Conservative measures such as decreased activity, splinting, anti-inflammatory medication, and corticosteroid injection should be attempted and can be effective in all stages of osteoarthritis.<sup>11</sup> Surgical intervention should be delayed until nonsurgical treatment has been exhausted.

Arthrodesis can afford excellent pain relief<sup>12</sup> and might be the better option for patients with major bone loss, fixed flexion contractures, central slip deficiency, angular deformity, previous infection, or severely damaged surrounding soft tissue.<sup>17</sup> Traditionally, it has also been the preferred method of treatment in the index finger, where pinch strength and lateral stability are required. Active patients find arthrodesis an unpalatable option for the middle and ring fingers, where grip strength and maximum arc of motion are more important, particularly for gripping a golf club.<sup>12</sup>

Arthroplasty provides both pain relief and restoration of joint motion and has seen advances in both technique and implant design since its inception in the late 1950s. The majority of cases in the literature performed through a volar approach have used silicone implants.

**TABLE 2. Preoperative and Postoperative Range of Motion Data**

Patient	Finger	Flexion Contracture (°)		Flexion (°)		Arc of Motion (°)	
		Pre	Post	Pre	Post	Pre	Post
1	Middle	5	0	45	68	40	68
2	Ring	20	0	45	85	25	85
3	Ring	20	0	60	65	40	65
4	Middle	30	15	55	70	25	55
5	Index, middle	20, 35	30, 30	55, 65	70, 75	35, 30	40, 45

Pre, preoperative; Post, postoperative.

Schneider<sup>10</sup> reported an average postoperative ROM of 48° (range, 5° to 85°) with only 2 revisions necessary in the group of 29 joints but hesitated to draw conclusions from a relatively short average follow-up period of 14 months. Lin et al described 69 silicone implant arthroplasties in patients with both osteoarthritis and inflammatory arthritis using a volar approach.<sup>11</sup> Range of motion across all patients was 46°, but the best postoperative ROM was seen in patients with osteoarthritis (an average of 58°) and the greatest improvement in ROM, from 26° before surgery to 39° after surgery, was seen in patients with posttraumatic arthritis.

Most of the reported series of PIP silicone arthroplasty have been performed through a dorsal approach. In these studies, postoperative ROM ranged from 49° to 56°. <sup>7,12,18</sup> Branam et al actually reported a decrease in average ROM after surgery (from 53° to 49°) in those patients (n=22 of 41 total) who received a silicone implant.<sup>7</sup> In total, results of silicone implant arthroplasty seem to be similar for dorsal and volar approaches. Complications with the silicone implant were noted across the board and included implant fractures, angular deformities, and erosion. <sup>7,11,12,14</sup>

Proximal interphalangeal joint SRA was developed in 1979 by Linscheid and Dobyns.<sup>4</sup> Their 2-piece bi-condylar implant was designed to better replicate anatomical motion. Recent studies have demonstrated better coronal plane angulation and patient satisfaction with equivalent pain relief and postoperative ROM when compared to the silicone implant.<sup>7</sup>

The first study to include different approaches for SRA of the PIP joint was published by Linscheid et al<sup>3</sup> in 1997 and included 66 joint replacements in 47 patients over a 14-year period. The vast majority of these procedures were performed through a dorsal extensor-splitting approach, and only 10 were done using a volar approach. Postoperative ROM was 47° and was re-

ported only for the group as a whole. The best results were obtained in patients with degenerative joint disease. Good or fair results were reported in 79% of joints implanted through a dorsal approach, and in only 6 of the 10 cases (60%) using the volar approach. Notably, 4 of the 10 volar approach patients had fixed swan-neck deformity and the authors stated “complications tended to reflect preoperative status.”

Johnstone reported excellent long-term pain relief in 18 of 20 joints, all but 2 of which were osteoarthritic or posttraumatic, using exclusively the dorsal approach.<sup>5</sup> The average postoperative ROM for the first 10 joints of the series was 37°, but it improved to 77° for the last 10 joints. The rate of subsidence in cemented joints (4%) was compared to uncemented joints (68%) in a later study, and the authors indicated a strong preference for cement use.<sup>19</sup> Johnstone postulated that an aggressive and early mobilization regimen was important in achieving good ROM and that final outcome might be further improved by enhancing preoperative ROM.

In 2008, Jennings and Livingstone reported on 43 PIP joint replacements with an average follow-up of 27 months using the dorsal approach in all but 6 cases, where the volar approach was used.<sup>6</sup> This is, to our knowledge, the only study to report separate outcomes for PIP SRA using a volar approach. Forty-one of the procedures were performed for osteoarthritic or posttraumatic arthritis and 2 for rheumatoid arthritis. Average postoperative ROM was 58° (preoperative average ROM was 57°) with no significant difference seen between dorsal and volar approaches. The ROM improved an average of 2° in cases in which the volar approach was used and 7° in cases in which the dorsal approach was used, but these differences were also not significant. Eleven revisions were performed, 10 of which were to correct loosening due to lack of cement.

In addition to the initial cobalt-chromium/ultra-high molecular weight polyethylene implant design studies, there have been studies of PIP SRA using a pyrolytic carbon implant.<sup>7-9</sup> Tuttle and Stern and Bravo et al both used the dorsal approach.<sup>8,9</sup> Postoperative ROM results were in the same 40° to 60° range as most studies discussed earlier, with average ROM of 53° at average follow-up times of 13 months<sup>13</sup> and 19 months<sup>7</sup> and 47° at an average follow-up time of 37 months.<sup>9</sup> Tuttle and Stern noted complications in all but 3 joints, the most common being squeaking of the implant, contracture, and deformity, and admitted to largely unpredictable and varied results. Bravo et al did not observe any cases of squeaking joints and described minimal extension lag and good lateral and coronal alignment in most patients.

The dorsal approach remains the more frequently used technique because of its versatility and the surgeon's ability to treat various abnormalities of the extensor mechanism. The volar approach for PIP SRA has not been adequately evaluated. Although results with the dorsal approach are generally satisfactory, preservation of the extensor mechanism as well as early motion and rehabilitation are appealing indications for the volar approach, particularly in an active or high-demand patient.

We present 35-month average follow-up on a cohort of 6 PIP SRAs in active patients using a volar approach. This pilot series demonstrates that the volar approach can provide excellent postoperative motion in this high-demand group, with minimal complications. Because of the small number of patients in this series, it is difficult to directly compare the results with previous studies, although the final range of motion in this cohort compares favorably with all previous studies. Our results would support previous findings that demonstrate improved results in patients with osteoarthritis or posttraumatic arthritis.<sup>3,6,10,11,13</sup> In 3 of the 6 cases, the volar approach was associated with no extensor deficits; the maintenance of the integrity of the extensor apparatus would appear to be a distinct advantage of this approach.

The average increase in arc of motion of 27° reported in this series is better compared to other studies of PIP SRA. Johnstone<sup>5</sup> reported an average increase of 20°, but other studies<sup>6-9</sup> have reported no noteworthy changes in arc of motion after surgery for patients with osteoarthritis or posttraumatic arthritis. We believe that the increase in arc of motion seen in our patients with osteoarthritis or posttraumatic arthritis can be attributed to minimal disruption of the soft tissue sleeve and

extensor mechanism and to the ability to begin full active ROM exercises within 3 days after surgery.

The 2 smallest arcs of motion and the 2 largest flexion contractures were seen in the oldest patient included in the series, an 89-year-old patient. At the time of surgery, this patient had diffuse osteoarthritis in all joints of both hands and lower extremities and had long-standing contractures in both hands. Despite these findings, which likely contributed to her modest improvement in arc of motion and persistent flexion contractures after surgery, this patient still plays golf and tennis twice weekly and reported only mild pain (2 on a scale of 1-5 according to a DASH questionnaire) 1 year after surgery. Excluding our elderly patient, the average arc of motion for the other 4 joints was 68° (range, 55° to 85°) with 1 flexion contracture of 15°.

The only complication in our series was subsidence of our only uncemented implant. We agree with other authors<sup>5,6,19</sup> who have concluded that cemented implants offer the best probability of avoiding subsidence and loosening. Although we have insufficient data to make a definitive conclusion regarding subsidence, our current approach is to broach the canals to accept a sufficiently large component that will provide maximal coverage of the cortical columns of the phalanges.

Although we believe that the volar approach offers distinct advantages over the dorsal approach in patients without extensor tendon dysfunction, the surgeon's level of comfort with each approach is important in deciding which to use. Early ROM and rehabilitation is possible with volar approach to PIP SRA, helping active individuals achieve desired increases in ROM. This case series demonstrates compelling data for a prospective, randomized study comparing dorsal and volar approaches to PIP SRA in active patients with osteoarthritis and posttraumatic arthritis.

## REFERENCES

1. Brannon EW, Klein G. Experiences with a finger-joint prosthesis. *J Bone Joint Surg* 1959;41A:87-102.
2. Flatt AE. The prosthetic replacement of rheumatoid finger joints. *Rheumatism* 1960;16:90-97.
3. Linscheid RL, Murray PM, Vidal MA, Beckenbaugh RD. Development of a surface replacement arthroplasty for proximal interphalangeal joints. *J Hand Surg* 1997;22A:286-298.
4. Linscheid RL, Dobyns JH, Beckenbaugh RD, Cooney WP III. Proximal interphalangeal joint arthroplasty with a total joint design. *Mayo Clin Proc* 1979;54:227-240.
5. Johnstone BR. Proximal interphalangeal joint surface replacement arthroplasty. *Hand Surg* 2001;6:1-11.
6. Jennings CD, Livingstone DP. Surface replacement arthroplasty of the proximal interphalangeal joint using the PIP-SRA implant: results, complications, and revisions. *J Hand Surg* 2008;33A:1565.e1-e11.
7. Branam BR, Tuttle HG, Stern PJ, Levin L. Resurfacing arthroplasty versus silicone arthroplasty for proximal interphalangeal joint osteoarthritis. *J Hand Surg* 2007;32A:775-788.

8. Tuttle HG, Stern PJ. Pyrolytic carbon proximal interphalangeal joint resurfacing arthroplasty. *J Hand Surg* 2006;31A:930–939.
9. Bravo CJ, Rizzo M, Hormel KB, Beckenbaugh RD. Pyrolytic carbon proximal interphalangeal joint arthroplasty: Results with minimum two-year follow-up evaluation. *J Hand Surg* 2007;32A:1–11.
10. Schneider LH. Proximal interphalangeal joint arthroplasty: the volar approach. *Semin Arthroplasty* 1991;2:139–147.
11. Lin HH, Wyrick JD, Stern PJ. Proximal interphalangeal joint silicone replacement arthroplasty: clinical results using an anterior approach. *J Hand Surg* 1995;20A:123–132.
12. Pellegrini VD Jr, Burton RI. Osteoarthritis of the proximal interphalangeal joint of the hand: arthroplasty or fusion? *J Hand Surg* 1990;15A:194–209.
13. Takigawa S, Meletiou S, Sauerbier M, Cooney WP. Long-term assessment of Swanson implant arthroplasty in the proximal interphalangeal joint of the hand. *J Hand Surg* 2004;29A:785–795.
14. Swanson AB. Flexible implant arthroplasty of the proximal interphalangeal joint of the fingers. *Ann Plast Surg* 1979;3:346–354.
15. Herren DB, Simmen BR. Palmar approach in flexible implant arthroplasty of the proximal interphalangeal joint. *Clin Orthop Relat Res* 2000;371:131–135.
16. Duncan SF, Merritt MV, Kakinoki R. The volar approach to proximal interphalangeal joint arthroplasty. *Tech Hand Up Extrem Surg* 2009;13:47–53.
17. Kobayashi KY, Terrono AL. Proximal interphalangeal joint arthroplasty of the hand. *J Am Soc Surg Hand* 2003;3:219–226.
18. Swanson AB, Leonard JB, deGroot Swanson G. Implant resection arthroplasty of the finger joints. *Hand Clin* 1986;2:107–117.
19. Johnstone BR, Fitzgerald M, Smith KR, Currie LJ. Cemented versus uncemented surface replacement arthroplasty of the proximal interphalangeal joint with a mean 5-year follow-up. *J Hand Surg* 2008;33A:726–732.